

# The Effect of Shock Wave Therapy on Patellar Ligament Desmitis after Tibial Plateau Leveling Osteotomy

Alissa Gallagher, DVM, Alan R. Cross, DVM, Diplomate ACVS, and Gustavo Sepulveda, DVM, Diplomate ACVR

Georgia Veterinary Specialists, Sandy Springs, GA

## Corresponding Author

Alissa Gallagher, DVM, Carolina Veterinary Specialists, 2225 Township Road, Charlotte, NC 28273  
E-mail: adgall281@hotmail.com

Received December 2011

Accepted December 2011

DOI:10.1111/j.1532-950X.2012.00958.x

**Objective:** To determine if shock wave therapy (SWT) after tibial plateau leveling osteotomy (TPLO) has a beneficial effect on patellar ligament inflammation assessed by thickening of the ligament and ligament fiber disruption.

**Study Design:** Prospective, randomized, controlled clinical trial.

**Animals:** Dogs (n = 30).

**Materials and Methods:** Dogs that had TPLO (July 1, 2009 to June 1, 2010) were enrolled. The affected stifle was examined by radiographs and ultrasonography preoperatively and 4, 6, and 8 weeks after TPLO. At 4 and 6 weeks, dogs in the treatment group were briefly anesthetized and treated with SWT. Patellar ligament thickness on a lateral radiographic projection was measured at 1/4, 1/2, 3/4 of the distance from origin to insertion. Ultrasound images were evaluated for patellar ligament disruption and periligament edema.

**Results:** There was significant difference in thickness ( $P = .0264$ ) only at the distal point; therefore, only this point was used to measure difference between the control and treatment groups. A significant difference between groups was reached at 6 and 8 weeks ( $P = .0059$  and  $P = .0095$ , respectively) postoperatively. No significant ultrasonographic differences were found.

**Conclusion:** Based on these results, SWT decreases the radiographic signs of patellar ligament desmitis.

Inflammation of the patellar ligament has been reported after the tibial plateau leveling osteotomy (TPLO).<sup>1-4</sup> Inflammation of the patellar ligament can range from asymptomatic ligament thickening, an incidental finding on postoperative radiographs, to clinical desmitis.<sup>3</sup> Findings on radiographs in dogs with desmitis include soft tissue swelling, thickening at the level of the tuberosity, and irregular ligament margins.<sup>1</sup> Findings on ultrasound in dogs with desmitis include thickening, disruption of fiber orientation, hypoechoic or anechoic core lesions<sup>5</sup>, and increased echogenicity of periligamentous tissues.<sup>3</sup> Clinical desmitis includes these radiographic and ultrasound findings as well as pain on palpation and lameness with activity.<sup>1</sup> The cause of these ligament changes is unknown but some proposed mechanisms include increased ligament strain or load, intraoperative trauma to the ligament, vascular damage during the surgical procedure, excessive postoperative activity, or alterations in stifle biomechanics.<sup>1,3</sup> Carey et al identified a cranial osteotomy, partial cranial cruciate ligament tear, and tibial tuberosity fracture as risk factors for patellar ligament inflammation.<sup>1</sup> Patellar ligament inflamma-

tion appears self limiting but severe cases can cause marked lameness and prolonged recovery from TPLO.

Mattern et al measured patellar ligament thickening radiographically and ultrasonographically after TPLO. Of 31 dogs, 27 had ultrasonographically measurable ligament thickening compared with preoperative values and 13 had desmitis defined as fiber disruption and changes in echogenicity 4 weeks after TPLO.<sup>3</sup>

Shock wave therapy (SWT) was first used in the mid 1960s for treatment of urolithiasis, then in the mid 1980s for treatment of orthopedic diseases.<sup>6</sup> In people, some of the diseases commonly treated include plantar fasciitis, lateral humeral epicondylitis (tennis elbow), and patellar desmitis (jumper's knee). Applications include treatment of nonunion fractures,<sup>7</sup> tendon and ligament injuries,<sup>5,8-12</sup> osteoarthritis,<sup>12,13</sup> and nonhealing wounds.<sup>14</sup> Use in veterinary medicine is common in equids for diseases such as suspensory ligament desmitis, and superficial digital flexor tendonitis.<sup>5,10,12,15</sup> Applications in dogs include osteoarthritis,<sup>13</sup> Achilles tendon strain injuries,<sup>16</sup> and calcifying supraspinatus tendinopathy.<sup>13</sup>

During SWT, acoustic waves are generated by an electrohydraulic transducer, focused, and directed into tissue. The peak energy level is high,  $\sim 0.04$ – $2.26$  mJ/mm<sup>2</sup>, but of short duration,  $\sim 1$   $\mu$ s.<sup>17</sup> The energy is absorbed in the

Presented in part at the Veterinary Orthopedic Society Conference, March 5–12, 2011, Snowmass, CO.

target tissue resulting in a number of biologic events. The complete mechanism of action in musculoskeletal disease is unknown; however, previous work has demonstrated stimulation of tissue neovascularization,<sup>8,10,11,15,18</sup> induction of transforming growth factor beta (TGF- $\beta$ ), insulin-like growth factor I (IGF-I),<sup>10,11,18</sup> and bone morphogenic protein 2 (BMP-2),<sup>18</sup> and possible increase collagen synthesis during early healing.<sup>18</sup> Wang et al demonstrated increased neovascularization at the tendon junction in dogs after SWT.<sup>16</sup>

Based on favorable results reported for treatment of tendon and ligament injuries in clinical and experimental studies in horses, people, and dogs, and experimental studies in rabbits, we investigated its use in the management of patellar desmitis after TPLO in dogs. Our hypothesis was that SWT would have a beneficial effect on patellar ligament inflammation after TPLO assessed by thickening of the ligament and ligament fiber disruption.

## METHODS AND MATERIALS

Large breed dogs (weighing >13.6 kg) admitted (July 1, 2009–June 1, 2010) for treatment of spontaneous unilateral rupture of the cranial cruciate ligament were invited to enroll in the study. Dogs were excluded if they had preexisting systemic disease, coexisting stifle conditions (patellar luxation, septic arthritis, etc.), other than osteoarthritis, or if they had previous surgery on the affected stifle.

Before surgery, the affected stifle was examined by radiographs and ultrasonography. The radiographic patellar ligament length was determined from lateral radiographic projections and divided into 4 equal segments. The radiographic ligament thickness was measured at 1/4, the ligament's center (1/2), and 3/4 the distance from its origin on the patella to its insertion on the tibial tuberosity. These measurement points were selected after the method of Mattern et al, which was based on ultrasonographic findings.<sup>3</sup> The distances were defined using the preoperative radiographs and the same points were used for postoperative measurements. A single blinded observer (AG) obtained all measurements.

Dogs were positioned in right lateral recumbency (as per the ultrasonographer's preference) with the stifle flexed to approximate a normal standing angle. Hair was clipped as necessary to evaluate the ligament. A linear array L12–5 and 38 mm probe (Phillips, Bothell, WA) was used in a longitudinal fashion to measure the length of the ligament and evaluate the fiber orientation and edema. The ultrasound images were evaluated for patellar ligament fiber disruption and periligament edema. Ligament pathology was graded on a scale from 1 to 4 (similar scoring system to Mattern et al<sup>3</sup>) where grade 1 = normal (Fig 1A), grade 2 = fibers that were mild to moderately disrupted (hyperechoic, Fig 1B), grade 3 = fibers that were severely disrupted (large hyperechoic areas, Fig 1C), grade 4 = fibers that were severely disrupted with periligament edema (Fig 1D). The

ultrasonographer (GS) was blinded to treatment group assignment. Dogs were randomly assigned to treatment or control groups by coin toss. Anesthetized dogs had TPLO performed by 1 of 3 board-certified surgeons. At 4, 6, and 8 weeks, the affected stifle was examined radiographically and ultrasonographically, and ligament measurements were obtained as described earlier.

At 4 and 6 weeks, dogs in the treatment group were briefly anesthetized with propofol (4–6 mg/kg intravenously [IV] to effect). After taking radiographs and ultrasonographic examination, a shock wave generator (PulseVet<sup>®</sup> VersaTron 4-Paws<sup>®</sup> machine, Alpharetta, GA) was used to deliver 600 shocks at energy level 6 (0.15 mJ/mm<sup>2</sup>) with a 5-mm Trode focused on the patellar ligament.

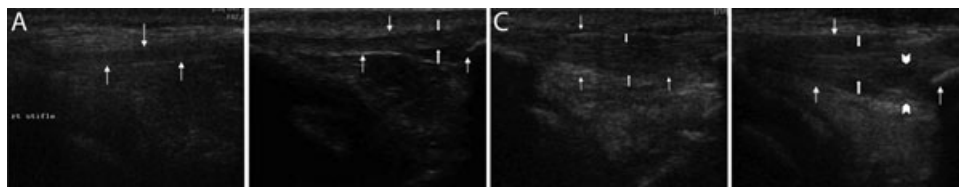
A repeated measures ANOVA (MIXED procedure in SAS, version 9.2, SAS Institute, Cary, NC) was used to evaluate the effects of SWT on ligament thickness. The model included treatment, time, and the time by treatment interaction as fixed effects. Additionally, a repeated measures ANCOVA (MIXED procedure, SAS version 9.2) was used to evaluate the effects of SWT on ligament thickness with week 4 values as a covariate, treatment, time (weeks 6 and 8), and the time by treatment interaction as fixed effects. If the interactions were significant at  $P < .05$ , within time point treatment effects were evaluated with the least squares mean. If the interaction was not significant, the main effect of treatment was assessed. Ultrasound scores were evaluated as ordinal data with repeated measures using the model above (the GLIMMIX procedure in SAS); however the algorithm used in this procedure would not converge, and the ANOVA was applied.

## RESULTS

Thirty dogs were enrolled in the study; 16 neutered females, 1 intact female, 12 neutered males, and 1 intact male. Mean age was 5.7 years (range, 1.5–12 years) and 5.8 years (range, 1–8 years), in the treatment and control groups, respectively. Mean weight was 31.8 kg (range, 13.9–50 kg) and 37.9 kg (range, 27.7–58.4 kg), in the treatment and control groups, respectively. Nineteen dogs were assigned to the treatment group and 11 to the control group.

Two (6.6%) dogs (both in the treatment group) had no ultrasonographic change and no change in ligament thickness at any time point. All other dogs had radiographic thickening of the patellar ligament after TPLO.

There was not a significant difference in mean radiographic ligament thickness between groups at the 1/4 or 1/2 measurement points ( $P = .4075$  and  $P = .1633$ , respectively). There was a significant difference at the 3/4 measurement point,  $P = .0264$ ; therefore, only this point was used for further statistical analyses. Mean thickness was significantly lower in the treatment group at 6- and 8-week time points ( $P = .006$  and  $P = .01$ , respectively) compared with the control group (Table 1). Although there was not



**Figure 1** Ultrasonographic ligament scoring. Thin white arrows indicate the margins of the patellar ligament. Thick white arrows indicate the margins of ligament disruption. Arrowheads indicate the margins of periligament edema. Ligament pathology was graded after Mattern et al<sup>3</sup>: (A) grade 1 = normal; (B) grade 2 = fibers mild to moderately disrupted (hyperechoic); (C) grade 3 = fibers severely disrupted (large hyperechoic areas); and (D) grade 4 = fibers severely disrupted with periligament edema.

**Table 1** Least Square Means Thickness (cm) at 3/4 Distance by Group

| Time (weeks) | Control     | Treatment    | <i>P</i> -Value |
|--------------|-------------|--------------|-----------------|
| 0            | 0.25        | 0.24         | 0.8719          |
| 4            | 0.77        | 0.64         | 0.2362          |
| <b>6</b>     | <b>0.87</b> | <b>0.56*</b> | <b>0.0059</b>   |
| <b>8</b>     | <b>0.83</b> | <b>0.54*</b> | <b>0.0095</b>   |

**Table 2** Least Square Means Thickness Measurements (cm) by Group and Pooled Using 4-Week Values as Covariates

|        | Control | Treatment | <i>P</i> -Value |
|--------|---------|-----------|-----------------|
| @1/4   |         |           |                 |
| 6      | 0.47    | 0.42      | NA              |
| 8      | 0.46    | 0.44      | NA              |
| Pooled | 0.47    | 0.43      | NA              |
| @1/2   |         |           |                 |
| 6      | 0.65    | 0.52      | NA              |
| 8      | 0.63    | 0.53      | NA              |
| Pooled | 0.64    | 0.52      | NA              |
| @3/4   |         |           |                 |
| 6      | 0.80    | 0.61      | NA              |
| 8      | 0.75    | 0.58      | NA              |
| Pooled | 0.78    | 0.59      | 0.0249          |

**Table 3** Mean Ultrasound Score by Time and Group

| Time (weeks) | Control | Treatment |
|--------------|---------|-----------|
| 0            | 1       | 1         |
| 4            | 2.5     | 2.2       |
| 6            | 2.6     | 2.4       |
| 8            | 2.5     | 2.3       |

a statistically significant difference in mean thickness between groups at 4 weeks (before treatment), mean ligament thickness was higher in the control group compared with the treatment group. To eliminate this finding as a possible confounder, the 4-week values were used as covariates in a separate analysis. In this analysis, ligament thickness was significantly lower in the treatment group versus the control at the pooled 6- and 8-week time points ( $P = .025$ ; Table 2). Differences in pooled thickness values at the other 2 measurement points did not reach statistical significance. Statistical significance was not reached in ultrasound scores between treatment and control groups (Table 3).

## DISCUSSION

None of these dogs had obvious clinical signs of patellar desmitis (prolonged lameness or pain on patellar tendon palpation) therefore, desmitis was diagnosed using postoperative radiographs and ultrasonography. We found 93% of dogs had patellar desmitis based on 4-week postoperative radiograph measurements. The reported incidence of radiographic evidence of patellar ligament desmitis after TPLO is reported as 5%,<sup>1</sup> 80%,<sup>3</sup> and 100%.<sup>4</sup>

We found a statistically significant ( $P = .0264$ ) effect of SWT on ligament thickness (ie, decrease in thickness) when compared with controls at the  $\frac{3}{4}$  distance measurement point. Our data are in agreement with the findings of Carey et al and Mattern et al who reported that the most thickened area was the distal aspect of the patellar ligament.<sup>1,3</sup> We expect the effect of treatment would be greatest here because of the greater thickness. Carey et al proposed several reasons for this region to have more inflammation including placement of the antirotational pin, the force placed on this area by the quadriceps muscles during contraction, thermal damage, and retraction of the patellar ligament during the osteotomy.<sup>1</sup>

The energy flux we chose was based on previous recommendations of  $\sim 0.28$  mJ/mm<sup>2</sup> and 500–600 shocks for rabbit tendons<sup>19</sup> and current typical clinical use in dogs. To more closely approximate the clinical situation of treating existing disease, we chose treatment time points of 4 and 6 weeks after TPLO. Mattern et al found that 100% of dogs had radiographically apparent patellar ligament desmitis by 4 weeks after TPLO.<sup>3</sup> It is possible that there is greater benefit if treatment is applied at other time points. Similarly, the effect of treatment we observed may have been greater if we had measured the effect at other time points. Further work would be needed to optimize these times. We did not attempt to determine causes for patellar desmitis or further elucidate the mechanisms of SWT in this study.

The process of ligament repair includes angiogenesis, inflammation, fibrogenesis, and remodeling.<sup>11</sup> The proposed mechanisms of extracorporeal SWT on ligaments include stimulation of tissue neovascularization<sup>8,10,11,18</sup>, inducing TGF- $\beta$ , IGF-I,<sup>10,11,18</sup> and BMP-2 synthesis.<sup>18</sup> Hsu et al suggested that there is an increase in collagen matrix stimulated by SWT.<sup>19</sup>

Wang et al demonstrated neovascularization in rabbits by increased synthesis of endothelial nitric oxide synthetase (eNOS), vessel endothelial growth factor (VEGF), and proliferating cell nuclear antigen (PCNA) observed with immunohistochemical stains.<sup>8</sup> They also reported a significant increase in neovessels occurring 4–12 weeks postoperatively.<sup>8</sup> Kersh et al had similar findings of improved neovascularization.<sup>10</sup> Increased neovascularization is a potential explanation of the results we observed; however, histopathologic analysis would be necessary to confirm this, which is not practical in a clinical setting.

Chen et al showed that TGF- $\beta$  and IGF-I increased as did healing rates in the treatment of the Achilles tendonitis with SWT. TGF- $\beta$  and IGF-I promote ligament healing by regulating collagen metabolism and tenocyte proliferation. They suggested that SWT stimulates biochemical signals which release TGF- $\beta$  and IGF-I.<sup>11</sup> Bosch et al noted tendon disruption and loss of the regular collagen pattern in normal tendons when treated with SWT.<sup>9</sup> This may explain why we did not observe a significant difference in the ultrasonographic appearance between groups. Another potential explanation is the rate at which ligament fibers ultrasonographically return to normal is far longer than the study period.

Currently, desmitis is treated with nonsteroidal antiinflammatory drugs and rest. We have shown that SWT accelerates the resolution of the radiographic signs of patellar ligament desmitis. Based on our findings we believe SWT should be considered in the treatment of patellar desmitis after TPLO.

## ACKNOWLEDGMENT

We thank Steven Radecki for the statistical analysis.

## REFERENCES

- Carey K, Aiken SW, DiResta GR, et al: Radiographic and clinical changes of the patellar tendon after tibial plateau leveling osteotomy. *Vet Comp Orthop Traumatol* 2005;18:235–242
- Priddy NH, Tomlinson JL, Dodam JR, et al: Complications with and owner assessment of the outcome of tibial plateau leveling osteotomy for treatment of cranial cruciate ligament rupture in dogs: 193 cases (1997–2001). *J Am Vet Med Assoc* 2003;222:1726–1732
- Mattern KL, Berry CR, Peck JN, et al: Radiographic and ultrasonographic evaluation of the patellar ligament following tibial plateau leveling osteotomy. *Vet Radiol Ultrasound* 2006;47:185–191
- Pacchiana PD, Morris E, Gillings SL, et al: Surgical and postoperative complications associated with tibial plateau leveling osteotomy in dogs with cranial cruciate ligament rupture: 397 cases (1998–2001). *J Am Vet Med Assoc* 2003;222:184–193
- McClure SR, VanSickle D, Evans R: The effects of extracorporeal shock-wave therapy on the ultrasonographic and histologic appearance of collagenase-induced equine forelimb suspensory ligament desmitis. *Ultrasound Med Bio* 2004;30:461–467
- Shrivastava SK, Kailash. “Shock wave treatment in medicine.” *J Biosci* 2005;30:269–275.
- Wang CJ, Chen HS, Chen CE, et al: Treatment of nonunions of long bone fractures with shock waves. *Clin Orthop Relat Res* 2001;387: 95–101
- Wang CJ, Wang FS, Yang KD, et al: Shock wave therapy induces neovascularization at the tendon-bone junction: a study in rabbits. *J Orthop Res* 2003;21:984–989
- Bosch G, DeMos M, VanBinsbergen R, et al: The effect of focused extracorporeal shock wave therapy on collagen matrix and gene expression in normal tendons and ligaments. *Equine Vet J* 2009;41:335–341
- Kersh KD, McClure SR, Evans RB: The evaluation of extracorporeal shock wave therapy on collagenase induced superficial digital flexor tendonitis. *Vet Comp Orthop Traumatol* 2006;19:99–105
- Chen YJ, Wang CJ, Yang KD, et al: Extracorporeal shock waves promote healing of collagenase-induced Achilles tendinitis and increase TGF- $\beta$ 1 and IGF-I expression. *J Orthop Res* 2004;22:854–861
- Revenaugh MS. Extracorporeal shock wave therapy for treatment of osteoarthritis in the horse: clinical applications. *Vet Clin North Am Equine Pract* 2005;21:609–625
- Francis DA, Millis DL, Evans M, et al: Clinical evaluation of extracorporeal shock wave therapy for management of canine osteoarthritis of the elbow and hip joint. *31st Annual Conference Veterinary Orthopedic Society*, Big Sky, Montana. Feb. 22–27, 2004
- Meirer R, Kamelger FS, Huemer GM, et al: Extracorporeal shock wave may enhance skin flap survival in an animal model. *Br J Plast Surg* 2005;58:53–57
- Beale, BS: Shock wave therapy: more shock than wave? *13 ESVOT Congress*, Munich, 2006, pp 19–20 [http://www.ivis.com]
- Wang CJ, Huang HY, Pai CH: Shock wave enhanced neovascularization at the tendon-bone junction: an experiment in dogs. *J Foot Ankle Surg* 2002;41:78–84
- McClure S, Dorfmueller C: Extracorporeal shock wave therapy: theory and equipment. *Clin Tech Equine Pract* 2003;4:348–357
- Wang CJ, Wang FS, Yang, KD. Biological mechanism of musculoskeletal shockwaves. *International Society for Musculoskeletal Shockwave Therapy—ISMST* 2004;1:5–es 11
- Hsu RW-W, Hsu W-H, Tai C-L, et al: Effect of shock-wave therapy on patellar tendinopathy in a rabbit model. *J Orthop Res* 2004, 22:221–227